

# Intracranial Magnetic Resonance Venography of Superior Sagittal Sinus, Straight Sinus and Cerebral Venous Channels: Normal Anatomy and Variations in North Indian Population

Nitin Agarwal<sup>1</sup>, Rohini Pakhiddey<sup>2\*</sup>, Neel Chand Dhissa<sup>2</sup>

<sup>1</sup> Assistant Professor, Department of Anatomy, G.S Medical College, Pilkhuwa, Hapur, Uttar Pradesh, India

<sup>2</sup> Associate Professor, Department of Anatomy, ESIC Dental College & Hospital, sec 15, Rohini, Delhi, 110089, Delhi, India. Tel.: 9899988287

\*Corresponding Author:

Rohini Pakhiddey, Associate Professor, Department of Anatomy, ESIC Dental College & Hospital, sec 15, Rohini, Delhi, 110089, Delhi, India. Tel.: 9899988287

E-MAIL: [rohiniddey@gmail.com](mailto:rohiniddey@gmail.com)

Date of Submission: 02/12/2021

Date of Review: 21/02/2022

Date of Acceptance: 26/02/2022

## ABSTRACT

The intracranial dural venous sinuses can be injured leading to thrombosis with in the dural sinuses causing headache, abnormal vision, weakness of the face and limbs on one side of the body, and seizures. Magnetic Resonance Venography (MRV) is one of the preferred methods of evaluation of the cerebral venous sinus anatomy, variations and pathology, particularly in the diagnosis of venous sinus thrombosis.

The purpose of this study is to evaluate the use of MRV to depict the normal intracranial venous anatomy and its variants in North Indian population which can help to avoid potential pitfalls in the diagnosis of dural venous sinus thrombosis, venous infarcts and venous hemorrhage.

**Aim:** The purpose of this study is to evaluate the use of MRV to depict the normal intracranial venous anatomy and its variants in North Indian population, which can help to avoid potential pitfalls in the diagnosis of dural venous sinus thrombosis, venous infarcts and venous hemorrhage.

**Materials:** The present study was undertaken in the Departments of Anatomy and Radiodiagnosis at a North Indian tertiary care teaching hospital over a period of two years. Magnetic Resonance Venograms (MRV) of patients attending the radiology department were used to study the normal anatomy and variations in the dural venous sinuses. 50 MRV scans of which 26 were of females and 24 of male, were included in the study. Anatomical variations and variations in drainage of the dural venous sinuses were assessed and statistical analysis was done.

**Results:** For both superior sagittal sinus drainage and straight sinus drainage, the proportion of veins draining in right and left transverse sinuses and confluence of sinuses was significantly different in the two age groups ( $p < 0.001$ ) in both males and females. Partial splitting of superior sagittal sinus in anterior one third or posterior one third was

also seen. Statistically significant findings were observed regarding the laterality for vein of Labbe & vein of Trolard.

**Conclusion:** MR venography is an excellent diagnostic technique to visualise anatomy and anatomic variations of venous sinuses as observed in our study. The partial splitting of superior sagittal sinus in either anterior one third or posterior one third as seen in our study, can cause misdiagnosis of thrombosis. Hence, knowledge of normal anatomy and anatomic variations in the intracranial venous sinuses is very important to diagnose cerebral venous sinus thrombosis accurately.

**KEYWORDS:** Anatomical Variations, Cerebral Venous Thrombosis, Dural Venous Sinus, Headache, Magnetic Resonance Venography

## INTRODUCTION

In adult mammals, the meninges are made of three distinct layers: the outermost dura mater, the middle arachnoid mater, and the innermost pia mater. The duramater is a thick layer made of collagenous fibres and is further composed of two layers - the outer layer (called endosteal layer or periosteal layer) serves as the periosteum of the internal surface of the skull bone. The inner layer (called meningeal layer or dura mater proper) is fused to the endosteal layer in most regions except where dural venous sinuses separate the two layers [1]. The dural venous sinuses are venous channels situated between the two layers of duramater and participates in venous drainage from the brain. Some dural sinuses close to the cranium also functions in osseous venous drainage through the meningeal veins [2].

The dural venous sinuses receive blood from the external and internal veins of brain, and receive cerebrospinal fluid (CSF) from the subarachnoid space and ultimately drain into the internal jugular veins. The dural venous sinuses are classified into : Unpaired ( Superior sagittal , Inferior

sagittal , straight , occipital , anterior intercavernous , posterior intercavernous and basilar venous plexus ) and Paired ( Transverse , Sigmoid , Cavernous , Superior and Inferior petrosal , Sphenoparietal ). These intracranial dural venous sinuses can be injured in skull fracture damaging the duramater and leading to thrombosis within the dural venous sinuses.

Many methods are being used to evaluate the anatomy and pathology of cranial venous sinuses and of these. The use of magnetic resonance venography (MRV) has got several advantages as compared to other methods as images can be acquired in 5-6 minutes duration and no contrast media is used to acquire venography images. Therefore, its use in evaluating intracranial venous system is increasing in frequency, particularly in the diagnosis of venous sinus thrombosis.

In order to accurately interpret the images obtained by MRV of cranial venous sinuses, it is important to have a precise knowledge of cerebral venous anatomy and of its anatomic variants. The normal anatomy, variants, and pitfalls on two dimensional (2D) time of flight (TOF) MRV in the paediatric population have been described [3]. Many studies have also been done to investigate the normal anatomy and variations of cranial venous sinuses in western population in both adults and pediatric age groups. The present study was undertaken as a step to evaluate the use of MRV to display the normal intracranial venous anatomy and its variants in Indian population which can help to avert any pitfalls in the diagnosis of dural venous sinus thrombosis and other cerebrovascular accidents. As studies in reference to North Indian population is lacking so the present study is a step which will fill the gap with appropriate data.

## MATERIALS

The present study was undertaken in the Departments of Anatomy and Radiodiagnosis at a North Indian tertiary care teaching hospital over a period of two years. Magnetic Resonance Venograms (MRV) of patients attending the radiology department were used to study the normal anatomy and variations in the dural venous sinuses. We organized the MRV films according to the age and sex of the patients to get a more statistically significant data. We could collect 50 films of which 26 were of female patients and 24 of male patients. We further segregated the MRV into two groups according to age (more than 40 years and less than 40 years). MRV of patients who had no known neurological disorder, confirmed by the details mentioned in the patient record form which included personal details of the patients, case history comprising of symptoms, signs, personal history, physical examination, laboratory test finding and imaging diagnosis, were included in the study. Only those films which didn't show any evidence of any space occupying lesion or infarct were studied. MR Venograms were collected on the day of imaging and data of all patients was stored in Dicom format. The Dicom images were opened into e-film software for analysis.

## Image Analysis

2D MRV Imaging findings of the following veins and sinuses were recorded: superior sagittal sinus , occipital sinuses, inferior Sagittal sinus, straight sinuses, basal vein of Rosenthal, vein of Galen, vein of Trolard, vein of Labbe, were recorded. Any anatomic variants in these sinuses or their drainage, if any, were recorded.

## Statistical Analysis

The data was statistically analysed using SPSS for windows 16.0 programmed. Chi-square ( $\chi^2$  analysis) contingency analysis was used to explore the relationship between ages, sex and drainage pattern of the cerebral venous sinuses.

## RESULTS

### Incidence of drainage pattern of Superior Sagittal sinus in male Table 1 Figures 1, 2 and 3

In male < 40 years age group, the Superior Sagittal Sinus was draining into right transverse sinus in 92% (n=12/13) and into left transverse sinus in 7% (n=1/13). No case showed drainage into both right and left transverse sinus or into confluence of sinuses.

In male >40 years of age the drainage was on right transverse sinus in 72% (n=8/11) subjects. Drainage into left transverse sinus, both right and left transverse sinus and into confluence of sinuses were 9% (n=1/11) for each type.

### Incidence of drainage pattern of Superior Sagittal sinus in females Table 1 Figures 1, 2 and 3

In females < 40 years age group the incidence of superior sagittal sinus draining into right and left transverse sinus was 65% (n=15/23) and 26% (n=6/23), respectively. The incidence of its drainage into both right and left transverse sinus and into confluence of sinus was 4% (n=1/23).

In females > 40 years age group the incidence was found to be same into right transverse sinus, left transverse sinus and both right and left transverse sinus which was 33% each (n=1/3 each).

### Incidence of drainage pattern of Straight sinus in male Table 2

Out of 13 MRV of male patients <40 years age group, the straight sinus was found to be draining into right transverse sinus in 5 cases (38%) and into left transverse sinus in 6 cases (46%). It was found to be draining into both right and left transverse sinus in 2 cases (15%).

Out of 11 MRV of male patients of age group >40 years, it was draining into right transverse sinus in 6 cases (54%) and into left transverse sinus in 3 cases (27%). The incidence of drainage into both right & left transverse sinus and into confluence of sinus was observed to be equal i.e. 9% (1 case each).

	Male cases (n=24)		Female cases (n=26)	
	< 40 yrs. (n= 13)	> 40 yrs. (n=11)	< 40 yrs. (n= 23)	> 40 yrs. (n=3)
Age	< 40 yrs. (n= 13)	> 40 yrs. (n=11)	< 40 yrs. (n= 23)	> 40 yrs. (n=3)
Rt. T.S	92%(n= 12)	72% (n=8)	65% (n= 15)	33%( n=1)
Lt. T.S	7% (n= 1)	9% (n=1)	26% ( n= 6)	33% (n=1)
Both Rt. & Lt. T.S	none	9% (n=1)	4% ( n= 1)	33% (n=1)
Confluence of venous sinuses	none	9% (n=1)	4% (n=1)	none

(Rt.T.S- right transverse sinus, Lt. T.S- left transverse sinus)

**Table 1: Incidence of drainage of Superior Sagittal Sinus**

### Incidence of drainage pattern of Straight sinus in female Table 3

The straight sinus was observed to be draining into right transverse sinus in 11 cases (47.3%), into left transverse sinus in 11 cases (47.3%) and into confluence of venous sinus in only 1 case (4.35%).

In the 3 cases belonging to >40 year age group, it drained into right transverse sinus in 1 case (33.3%), into left transverse sinus in 2 cases (66.7%).

#### Statistical significance

For both superior sagittal sinus drainage and straight sinus drainage, the proportion of veins draining in right and left transverse sinuses and confluence of sinuses was significantly different in the two age groups ( $p < 0.001$ ) in both males and females. Statistically significant difference was also observed between male and female patients ( $p < 0.007$ ).

### Incidence of Splitting Of Superior Sagittal Sinus :Table 3

Splitting of superior sagittal sinus was observed either in its anterior  $1/3^{rd}$  or in posterior  $1/3^{rd}$  part. The splitting was observed in posterior  $1/3^{rd}$  of the sinus in a male patient <40 year age group (8 %). In female in <40 year age group it was seen in 2 cases in anterior  $1/3^{rd}$  (8%) and in 1 case (4%). In >40year female age group it was seen in posterior  $1/3^{rd}$  only in 1 case (33%).

**Statistical analysis-** No statistical significant association was observed.

### Incidence of Basal Vein Table 4

The vein of Galen, Internal cerebral veins were observed in all the subjects in both the sexes. The Basal vein was found only in 40 % ( n= 20) subjects of which the pattern of distribution was 46.15 % ( n=6) in males <40 age group and 45.45 % ( n=5) in >40 age group. In females in <40 and >40year age group it was seen in 34.78 % ( n=8) and 33.3 % ( n=1) respectively. The Basal vein was not observed in 60 % ( n=30). Age wise no statistically significant difference was seen ( $p > 0.05$ ).

### Incidence of vein of Labbe in males Table 5 Figure 5

The total incidence in males was 67 % ( n=16/24) of which in <40 and >40 year age group was 76 % ( n=10/13) and 54 % ( n=6/11), respectively. In <40 year age group it was observed unilaterally on left side only in 23 % ( n=3/13). In >40years age group it was found unilaterally on right and left side in 9 % ( n=1/11) and 4 % ( n=4/11), respectively.

The vein of Labbe was present bilaterally in 53 % ( n=7/13) and 9 % ( n=1/11) in <40 and >40 year age group, respectively.

### Incidence of vein of Labbe in females Table 5 Figure 5

The incidence in females was 73 % ( n=19/26). In <40year age group it was present in 4 % ( n=1/23) and 39 % ( n=9/23) of patients in left and right side respectively. In >40 year females it was found only on left side in 33 % ( n=1/3) cases. The bilateral presence was observed only in <40year age group, the incidence of which was 34 % ( n=8/23).

### Incidence of vein of Trolard in males Table 5 Figure 6

Vein of Trolard was observed in 9 cases (37.5 %, n=9/24). In males <40years it was unilaterally present on right and left equally i.e. 15.38% ( n=2/13) each and in >40years age group it was seen only on left side in 27.7 % ( n=3/11). Its bilateral presence was observed in one subject each in <40 and >40 years age group.

### Incidence of vein of Trolard in females Table 5 Figure 6

Vein of Trolard was observed in 30.76 % ( n=8/26) cases. In females <40years it was observed unilaterally on right and on left side in 26 % ( n=6/23) and 4% ( n=1/23), respectively. Only bilateral presence was seen in 33 % cases in >40 year age group ( n=1/3).

#### Statistical analysis

Amongst unilateral findings, no significant association of right and left side was seen with age either amongst males or amongst females for veins of Trolard ( $p > 0.05$ ). However, for vein of Labbe, the incidence of right side was significantly higher than compared to left amongst females ( $p = 0.026$ ). However, no such association was seen amongst males.

No significant association with laterality was seen in either sex for either of the two veins in either age group ( $p > 0.05$ ). The proportion of left unilateral presence of Vein of Trolard

	Male cases (n=24)		Female cases (n=26)	
	< 40 yrs. (n= 13)	> 40 yrs. (n=11)	< 40 yrs. (n= 23)	> 40 yrs. (n=3)
Rt. T.S	38% (n= 5)	54% (n= 6)	47.3% (n= 11)	33.3%( n=1)
Lt. T.S	46% (n= 6)	27% (n=3)	47.3%% ( n= 11)	66.7% (n=2)
Both Rt. & Lt. T.S	15% (n=2)	9% (n=1)	none	none
Confluence of venous sinuses	none	9% (n=1)	4.35% (n=1)	none

(Rt.T.S- right transverse sinus, Lt. T.S- left transverse sinus)

**Table 2: Incidence of drainage of Straight Sinus**

Gender	Age (yrs.)	Splitting of superior sagittal sinus	
		Splitting in anterior 1/3rd (A3)	Splitting in Posterior 1/3rd (P3)
male	<40 (n=13)	0	1 (7.69%)
	>40 (n=11)	0	0
Female	<40 (n=23)	2 (8.7%)	1 (4.35%)
	>40 (n=3)	0	1 (33.33%)

**Table 3: Incidence of splitting of Superior Sagittal Sinus**

Gender	Age <40 yrs.	Age > 40 yrs.
Male	46.15% (n= 6/ 13)	45.5% (n=5/11)
Female	34.78%(n= 8/23)	33.3% (n= 3)

**Table 4: Incidence of Basal vein**

was significantly higher in males aged <40 years ( $p < 0.001$ ). The bilateral presence of the vein of Labbe was significantly higher in the lower age group ( $p < 0.001$ ).

#### Incidence of Inferior sagittal sinus

The cumulative incidence was observed to be 36 % (n=18/50). The incidence in male in <40 and >40 year age group was 38 % (n=5/13) and 54 % (n=6/11), respectively. In female it was observed only in <40 years age group, 30 % (n=7/23).

#### Incidence of Occipital sinus

The cumulative incidence was 2% (n=1/50). It was observed in one female subject in <40 year age group, (n=1/23, 4%). No statistically significant association with age was seen in either of the two sexes ( $p > 0.05$ ).

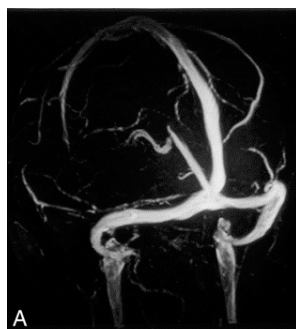#### DISCUSSION

Dural venous sinus thrombosis (DVST), usually presents with headache, seizures and loss of consciousness [4]. Dural venous sinus thrombosis can also be seen in a number of

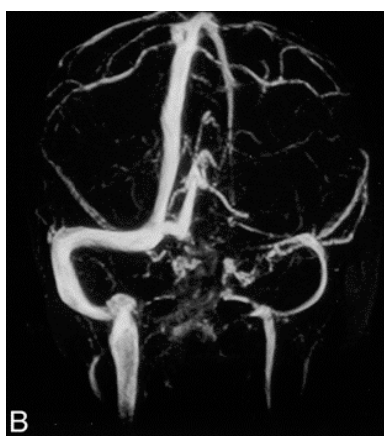conditions like, hypercoagulable states, dehydration, fection, tumor invasion, and in conjunction with oral contraception and may be a cause of neurologic deterioration in these cases. Since these symptoms may vary, sometimes it becomes very difficult for clinicians to diagnose dural venous sinus thrombosis and they have to depend on the radiological investigations. Venous catheter angiography is considered as the standard of reference for diagnosis of dural venous sinus thrombosis [5]. However, it is an invasive procedure and is associated with many risks [6]. MR angiography has proved to be one of the best methods of demonstrating venous sinus anatomy and venous sinus thrombosis replacing the conventional angiography [7, 8]. Many techniques of MR angiography are being used to study the anatomy of major cerebral venous sinuses. As observed by Liauw et al... both three-dimensional phase contrast MR angiography (3D PC MRA) and two dimensional time of flight (2D TOF) are accurate for visualising the anatomy of dural venous sinuses [9]. Narayanam et al. studied the anatomy of dural venous sinuses using 3D PC (phase contrast) MRA using 0.5 T equipment [10]. The phase contrast methods have major drawbacks as in the acquisition times are relatively

	Male cases ( n=24)		Female cases (n= 26)	
	Age <40 yrs. (n=13)	Age >40 yrs. ( n=11)	Age <40yrs. ( n= 23)	Age > 40 yrs.(n= 3)
<b>1.Vein of Trolard</b>				
<i>left sided</i>	15.38% ( n=2)	27.7% ( n= 3)	26% ( n=6)	none
<i>right sided</i>	15.38% ( n=2)	none	4% (n= 1)	none
<i>bilateral</i>	7.69% ( n=1)	9.09% (n= 1)	none	33% (n= 1)
<b>2. Vein of Labbe</b>				
<i>left sided</i>	23% ( n=3)	9% ( n=1)	4% ( n=1)	33% (n=1)
<i>right sided</i>	none	4% (n= 4)	39% (n= 9)	none
<i>bilateral</i>	53% ( n= 7)	9% ( n= 1)	34% (n= 8)	none

**Table 5: Incidence of Vein of Trolard and Vein of Labbe**



**Figure 1:** Right and left transverse sinuses are co-dominant. Both the superior sagittal and straight sinuses drain into the torcular herophili



**Figure 2:** Flow void is seen in left transverse sinus. The superior sagittal and straight sinuses drain into the right transverse sinus

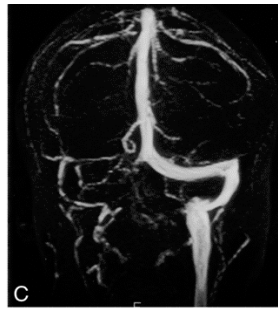


Figure 3: Right transverse sinus is absent. The right sigmoid sinus and internal jugular vein are atretic. The superior sagittal and straight sinuses drain into the left transverse sinus and then into the sigmoid sinus and left internal jugular vein

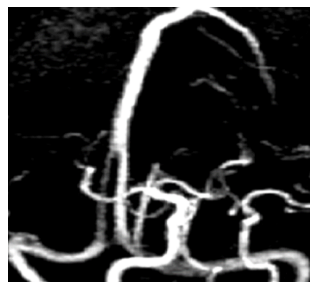

Figure 4: MR venogram showing splitting of Superior Sagittal Sinus in the posterior aspect

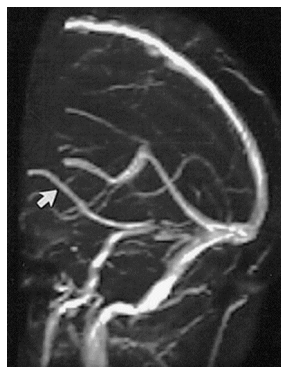

Figure 5: Arrow showing the Right Vein of Labbe

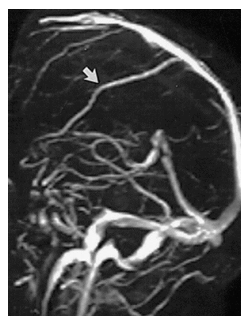

Figure 6: Arrow showing Right Vein of Trolard

lengthy, require prior estimate of blood flow velocity and also demand strong magnetic field gradient performance [11]. In our study, we were able to visualise superior sagittal sinus, the straight sinus, the vein of Galen, and the internal cerebral veins completely and there were no flow gaps noticed. Basal veins of Rosenthal as well as for an anastomotic vein of Labbe were also clearly visualised in our study. Our study was in agreement with a study done by Ayanzen et al. [12].

We also found out partial splitting of superior sagittal sinus in anterior one third and posterior one third in 5 cases (10%). The partial splitting of superior sagittal sinus especially in its posterior segment is associated with misdiagnosis of dural venous sinus thrombosis. The partial splitting of superior sagittal sinus can be explained by its embryological origin. Embryologically, superior sagittal sinus is derived from the marginal sinus present on either side which later fuse and give rise to the superior sagittal sinus. Failure of fusion or partial fusion of the marginal sinus may result in the partial split sinus [13]. Ruiz et al. reported the presence of occipital sinus in one of 12 cadavers they studied [14]. Occipital sinuses were reported in 18% in a study by Widjaja et al. [3]. Narayanam et al. identified occipital sinus in 17% of their patients [10]. Rollins et al. reported presence of occipital sinus only in 2% patients in age group of >2 years [15]. They also reported age related regression of occipital sinus. In our study occipital sinus was reported in 4.53% of the patients. Dora and Zileli concluded from their study that the presence of occipital sinus is related to the size of the lateral sinus [16].

Ruiz DSM et al concluded from their study that the occipital sinus may present singly, duplicated, or as a network of venous collaterals, and is present within the layers of duramater [14]. It connects the torcula with the Internal Jugular vein. It is thought that the occipital venous network involutes once most of the venous flow passes through the large dural sinuses as the child achieves an upright position [17]. This can explain the low incidence of occipital sinus in adults, as seen in our study too.

In our work, we could study only 50 MR venograms and only from a single hospital. We consider this as a limitation to our study and suggest that a multi centric study involving more number of MRV should be undertaken to have more statistically significant data on the normal anatomy and variations in the cerebral venous sinuses.

## CONCLUSION

MR venography is an excellent diagnostic technique to visualise venous sinuses especially superior sagittal sinus, the straight sinus, the vein of Galen, and the basal veins of Rosenthal as well as for an anastomotic vein of Labbe, as observed in our study. The partial splitting of superior sagittal sinus in either anterior one third or posterior one third as seen in 5 cases (10%) in our study, can cause misdiagnosis of thrombosis. Hence, knowledge of normal

anatomy and anatomic variations in the intracranial venous sinuses is very important to diagnose cerebral venous sinus thrombosis accurately.

## REFERENCES

1. Adeeb N, Mortazavi MM, Tubbs RS, Cohen-Gadol AA. The cranial dura mater: a review of its history, embryology, and anatomy. *Childs Nerv Syst*;28:827–837.
2. Mancall LM, Brock DG. *The Anatomical Basis for Clinical Neuroscience*. In: Gray's Clinical Neuroanatomy. Philadelphia: Elsevier Saunders ; .
3. Widjaja E, Griffiths PD. Intracranial MR Venography in Children: Normal Anatomy and Variations. *American Journal of Neuroradiology*. 2004;25:1557–1562.
4. Bousser MG, Chiras J, Bories J, Castaigne P. Cerebral venous thrombosis - a review of 38 cases. *Stroke; A journal of cerebral circulation*. 1985;16:199–213.
5. Casey SO, Alberico RA, Patel M, Jimenez JM, Ozsvath RR, Maguire WM et al. Cerebral CT venography *Journal of Radiology*. 1996;198:163–170.
6. Heiserman JE, Dean BL, Hodak JA, Flom RA, Bird CR, Drayer BP et al. Neurologic complications of cerebral angiography. *American Journal of Neuroradiology*. 2000;15:1401–1407.
7. Mattle HP, Wentz KU, Edelman RR, Wallner B, Finn JP, Barnes P et al. Cerebral Venography with MR. *Journal of Radiology*. 1991;178:453–458.
8. Padayachee TS, Bingham JB, Graves MJ, Colchester AC, Cox TC. Dural sinus thrombosis: diagnosis and follow-up by magnetic resonance angiography and imaging. *Neuroradiology*. 1991;33:165–167.
9. Liauw L, Buchem MAV, Spilt A, Bruine FTD, Berg RVD, Hermans J. MR angiography of the intracranial venous system. *Radiology*. 2000;214:678–82.
10. Surendrababu N, Subathira, Livingstone RS. Variations in the cerebral venous anatomy and pitfalls in the diagnosis of cerebral venous sinus thrombosis: Low field MR experience. *Indian Journal of Medical Sciences*. 2006;60:135–142.
11. Saloner D. The AAPM/RSNA physics tutorial for residents. An introduction to MR angiography. *Radiographics*. 1995;15(2):453–465.
12. Ayanzen RH, Bird CR, Keller PJ, McCully FJ, Theobald MR, Heiserman JE. Cerebral MR Venography: Normal Anatomy and Potential Diagnostic Pitfalls. *American Journal of Neuroradiology*. 2000;21:74–78.
13. Huang YP, Okudera T, Ohta T, Robbins A. Anatomic variations of the dural venous sinuses. *The Cerebral Venous System and Its Disorders*. 1984;p. 109–67.

14. Ruiz D, Gailloud P, Rufenacht DA, Delaville J, Henry F, Fasel J. The craniocervical venous system in relation to cerebral venous drainage. *American Journal of Neuroradiology*. 2002;23:1500–1508.
15. Rollins N, Ison C, Reyes T, Chia J. Cerebral MR Venography in children. *American Journal of Neuroradiology*. 2005;26:50–55.
16. Dora F, Zileli T. Common variations of the lateral and occipital sinuses at the confluens sinuum. *Journal of Neuroradiology*. 1980;20(1):23–27.
17. Okudera T, Huang YP, Ohta T. Development of posterior fossa dural sinuses, emissary veins, and jugular bulb: morphological and radiologic study. *American Journal of Neuroradiology*. 1994;15:1871–1883.

**How to cite this article:** Agarwal N, Pakhiddey R, Dhissa NC. Intracranial Magnetic Resonance Venography of Superior Sagittal Sinus, Straight Sinus and Cerebral Venous Channels: Normal Anatomy and Variations in North Indian Population. *Perspectives in Medical Research*. 2022;10(2):13-20  
DOI: [10.47799/pimr.1002.04](https://doi.org/10.47799/pimr.1002.04)