

## Chondroblastoma in distal femur

R Karthik Reddy<sup>1</sup>, M Nagendra Babu<sup>2</sup>, J Mothilal<sup>3</sup>, P Saiprashanth Reddy<sup>4</sup>

<sup>1</sup>Postgraduate Student, <sup>2</sup>Professor & Head, <sup>3</sup>Professor, <sup>4</sup>Assistant Professor, Department of Orthopedics, Prathima Institute of Medical Sciences, Karimnagar, Telangana, India.

Address for correspondence: Dr R Karthik Reddy, Postgraduate Student, Department of Orthopedics, Prathima Institute of Medical Sciences, Karimnagar, Telangana, India.

Email: karthikreddyratna@gmail.com

### ABSTRACT

Chondroblastoma was first described in detail by Codman in 1931 and so is occasionally referred to as Codman's tumor. Chondroblastoma is a rare primary benign bone tumor arising from immature cells of epiphyseal cartilage with preferential localization in the epiphysis or apophysis. Onset occurs before obliteration of the epiphyseal line, from 10 to 20 years of age. Males predominate with a ratio of 3 to 2. Chondroblastomas are generally treated by curettage with or without bone grafts. In this report, our aim was to present a rare tumor chondroblastoma which was localized in the distal femoral epiphysis.

**Keywords:** Chondroblastoma, Epiphyseal tumour, Curettage.

### INTRODUCTION

Chondroblastoma is a cellular, vascular, and cartilaginous tumor of young adults, occurring about the epiphyseal line, destroying cancellous bone, and characteristically containing multiple calcium deposits. Jaffe and Lichtenstein and the majority of reports consider the tumor benign<sup>1</sup>.

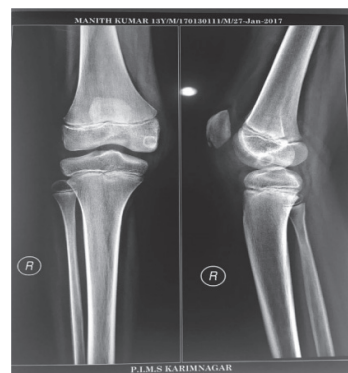Chondroblastoma was first described as calcified giant cell tumor by Ewing.<sup>1</sup> It is extremely rare and accounts for less than 1% of all primary bone tumors and most commonly originate from the epiphysis of long bones about the knee and upper humerus. Chondroblastoma is a rare primary benign tumor of bone with a relatively high incidence in older children.<sup>2</sup> In most cases it manifests between 10 to 20 years. Males predominate with a ratio of 3 to 2. Since the tumor is usually localized near a joint or growth plate, functional impairment and growth disturbances may be expected. Recurrences also are a major concern. Metastasis of a histologically benign chondroblastoma is rare.<sup>3</sup> The suggested treatment for aggressive chondroblastoma ranges from simple curettage to resection with a margin of surrounding normal tissue and structural reconstruction.<sup>2</sup>

### CASE REPORT

This is a 13 years old male patient who presented to us with a 3 months history of right knee pain. It is associated with night pain and rest pain. Lately the pain has got severe, causing difficulty in walking. There is no obvious swelling in knee joint. He finds it difficult in squatting and standing for long period of time. There are no constitutional symptoms such as loss of weight or appetite. There is no history of exposure to tuberculosis.

Examination revealed tenderness around medial side of knee joint more in proximal part and there is no obvious swelling and active range of motion of the knee is 10 to 100 degrees.

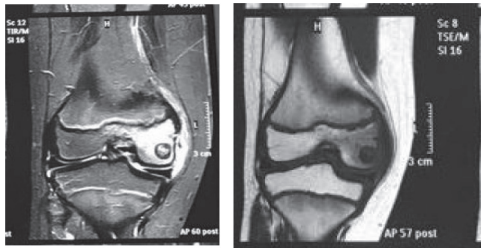
Radiographs done showed an osteolytic lesion in medial condyle of femur. There is no involvement of soft tissue



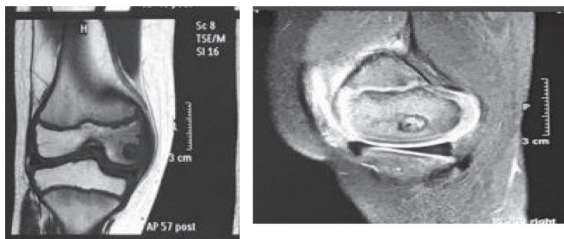
**Figure 1: Radiographs shows an osteolytic lesion in medial condyle of right femur**

Magnetic resonance scanning done showed a well-defined round T1 Hypointense T2 hyperintense eccentrically located lytic epiphyseal lesion with T1/T2 hypointense calcific rim located in the medial condyle of right femur associated with significant surrounding oedema suggestive of chondroblastoma [Figure 2,3&4]

**Figure 2: Magnetic resonance image showing features of chondroblastoma**

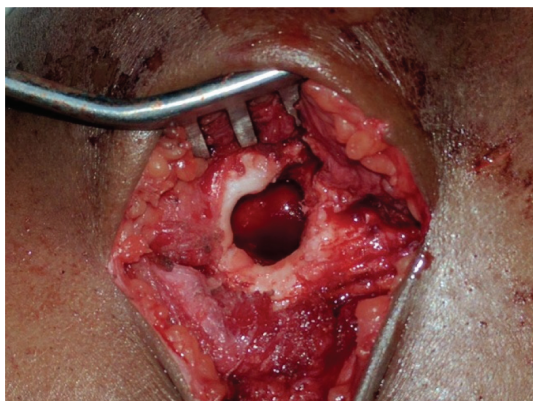


**Figure 3: Magnetic resonance scanning-  
Figure 4: Magnetic resonance scanning**



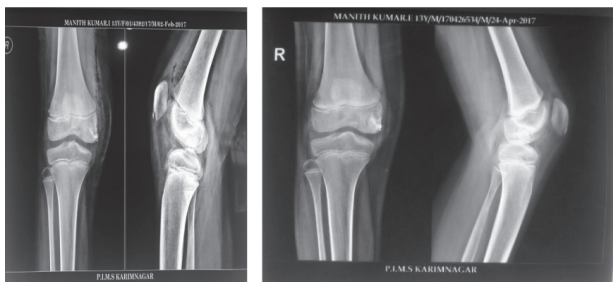
Curettage of the lesion done until margins of the lesion bleed and extending the curettage until the normal surrounding bone. Sample send for histopathological examination. Defect in the bone filled with allogeneous cancellous iliac crest bone graft from the father [Figure 5].

**Figure 5: Intraoperative image**



**Figure 6: Immediate Post-op X ray**

**Figure 7: 2.5 months X-ray**

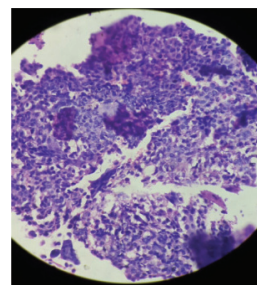


Postoperatively patient was put on knee brace. Isometric quadriceps muscle and straight leg raising exercises were initiated on the second postoperative day [Figure 6]. The brace was removed two weeks after the surgery. Active and active assisted range of motion exercises were initiated at that time. 2.5 months after the surgery, patient is ambulating full weight bearing with no pain.

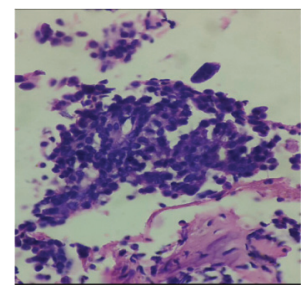
Follow-up was done at 2.5 months after curettage [Figure 7]. The lesion resolved with resolution of pain and swelling. Knee movements were not affected.

Histopathology confirms diagnosis of chondroblastoma [Figure 8&9].

**Figure 8**



**Figure 9**



**Figure 8&9: Section showing features of Chondroblastoma**

**Figure 8,9:** Showing small round to oval cells with round to oval nuclei showing fine chromatin with few showing occasional grooves and moderate amount of cytoplasm. At places vesicular cells are seen. Foci shows chondroid differentiation with peripheral calcification rimming. Also seen are areas of hyaline cartilage, lamellar bony trabeculae with haematopoietic elements

**DISCUSSION**

Chondroblastoma constitutes a very rare bone tumor entity.<sup>2,6</sup> In most cases it manifests between 10 to 20 years. Chondroblastoma are typically centered in an epiphysis. Although they occur most often in the end of a major tubular bone, they can appear in any secondary center of ossification, such as the greater trochanter.

In the literature, there are only three types of tumors that involve the physis. They are chondroblastoma, Giant cell tumor of the bone, and clear cell chondrosarcoma. Other possible differential diagnosis would be epiphyseal osteomyelitis. Roentgenograms show a characteristic well-delineated area of rarefaction of cancellous bone extending over and beyond the epiphyseal line quite early. The position is often eccentric in the epiphysis. The cortex may be thinned but rarely penetrated. The tumor borders are irregular, fuzzy and vague. This is in contrast with a giant-cell tumor, which shows well defined margins, and the cortex, although thinned, is elevated.

Chondroblastoma shows mottled areas of increased density throughout the tumor represent calcium deposits. Symptoms and findings are trauma, pain, tenderness, swelling in most cases, occasionally limp, joint effusion. Course is rapid from 1 month to 2 years. Penetration through the cortex into the soft tissues is seen only in a small percentage of cases.<sup>4</sup> The adjacent cortex is normal in only 15% of tumors (advanced and stage III lesions).<sup>5</sup> Three fourths of the tumors result in erosion and thinning of the involved cortical bone. Cortical destruction is unusual, occurring in 10% of cases.<sup>6,7</sup> The cortex is normal in 41% and completely destroyed in at least one region in up to 5% of cases.<sup>2,7,8</sup> Chondroblastoma in soft tissues tends to be well circumscribed and usually has a shell of ossification.<sup>2</sup>

Hence complete resection of the lesion is not difficult. Predominant secondary aneurysmal bone cyst like changes has been noted in up to 15% of chondroblastoma cases.<sup>9</sup> Some authors have suggested that recurrences are more common when aneurysmal bone cyst changes are present. Treatment for chondroblastoma consists of simple curettage, bone grafting, and possible cementation using similar techniques as for giant cell tumor surgery.<sup>8,9</sup> After intralesional resection, reconstruction can be accomplished with autograft or allograft or both. When treated with curettage these tumors seem to have a higher rate of recurrence.<sup>10</sup> Unni recommendations that aggressive lesions (lesions with cortical erosion or cortical breakthrough) should be treated with wide cortical saucerisation and curettage. Cryotherapy or phenol can be used as adjuvants.<sup>11</sup> Vascularised or cancellous autogenous grafts would give maximum bone incorporation but donor site morbidity limits their use

Secondary aneurysmal bone cyst-like changes were seen indeed in more than one-third of all lesions reported.<sup>12</sup>

The term chondroblastoma suggests a benign cartilage-forming tumor, but in fact this epiphyseal lesion of childhood has a histological appearance that is more typical of the benign metaphyseal-epiphyseal giant cell tumor seen in young adults.<sup>2</sup> Even though chondroblastoma is considered benign, on rare occasions it can metastasize to the lung.<sup>5</sup> Local recurrences after curettage range from 10% to 38%.

In conclusion, chondroblastoma is a rare primary benign bone tumor in the epiphysis that rarely causes cortex destruction. Curettage and obliteration of the cavity with autologous or allogeneous bone grafts is an effective treatment modality and these patients must be followed-up on a regular basis for immediate diagnosis of recurrence.

## REFERENCES

1. Codman EA: Epiphyseal chondromatous tumors of the upper end of the humerus. *Surg Gynecol Obstet* 52:543, 1931.
2. Unni K. Benign chondroblastoma. In: K. Krishnan Unni, Carrie Y. Inwards, eds. *Dahlin's Bone Tumors*. 6th ed. Philadelphia: Lippincott-Raven Publishers; 1996: 45-59.
3. Dahlin DC, Ivins JC. Benign chondroblastoma: a study of 125 cases. *Cancer*. 1972;30:401-4.
4. Caterini R, Manili M, Spinelli M. Epiphyseal chondroblastoma of bone: long-term effects on skeletal growth and articular function in 15 cases treated surgically. *Arch Orthop Trauma Surg*. 1992;111:327-31.
5. Riddell RJ, Louis CJ, Bromberger NA. Pulmonary metastases from chondroblastoma of the tibia: report of a case. *J Bone Joint Surg*. 1973;55-B:848-53.
6. Huvos AG, Marcove RC, Erlandson RA. Chondroblastoma of bone: a clinicopathological and electron microscopic study. *Cancer*. 1972;29:760-5.
7. Nagai M, Minami A. Recurrent benign chondroblastoma at the distal end of the radius. *J Hand Surg*. 1999;24-B:113-5.
8. Rana TA, Bohrer SP. Chondroblastoma. *South Med J*. 1992;85:668-72.
9. Ramappa A, Lee F, Tang P, Carlson J, Gebhardt M, Mankin H. Chondroblastoma of bone. *J Bone Joint Surg*. 2000;82-A:1140-5.
10. Kurt AM, Unni KK, Sim FH, Mcleone RA. Chondroblastoma of bone. *Hum Pathol*. 1989;20:965-70.
11. Ewing J. Chondroblastoma In *Neoplastic Diseases: A Treatise on Tumors*. 3rd ed. Philadelphia: WB Saunders; 1928:293.
12. Ramappa A, Lee F, Tang P, Carlson J, Gebhardt M, Mankin H. Chondroblastoma of bone. *J Bone Joint Surg*. 2000;82-A:1140-5.

**How to cite this article :** Karthik Reddy R, Nagendra Babu , Mothilal J, Saiprashanth Reddy. Chondroblastoma in distal femur. *Perspectives in Medical Research* 2017;5(3):74-76.

**Sources of Support:** Nil, Conflict of interest: None declared