

Fine needle aspiration cytology of Bone tumours in correlation with Histopathology

Kasture Santosh P¹, Kulkarni Dinesh R², Kokandakar Hemant R³, Bhatambrekar Shrikant V⁴

¹Associate Professor, Department of Pathology, M G M's Medical College, Aurangabad, ²Associate Professor, Department of Pathology, Bidar Institute of Medical Sciences, Bidar, ³Associate Professor, ⁴Ex Associate Professor, Department of Pathology, Government Medical College, Aurangabad.

Address for correspondence: Dr. Santosh Kasture, 55, Sarang housing society, Behind Bank of Baroda, Garkheda, Aurangabad – 431005, Maharashtra, India.

Email id :kasturesp11@yahoo.co.in

ABSTRACT

Introduction:

Fine Needle Aspiration cytology (FNAC) of bone tumors has now entered a phase of enthusiasm from initial skepticism. We carried out FNAC of bone tumors as a three years prospective study in 74 patients clinically suspected with bone tumors.

Objective:

The objective was to evaluate and establish FNAC as a routine procedure for bone tumors and to study the diagnostic accuracy by correlating cytological features with histopathology.

Materials & Methods: Sterile 21- 23 gauge needles with 10 - 20 cc syringes were used. All cases were studied under radiological and clinical guidance and also correlated with histopathology. Smears were stained by Papanicolou (PAP), Haematoxylin and Eosin (H & E) and Leishman stains.

Results: Overall diagnostic accuracy of FNAC bone tumors was 85.13%, for benign tumors 73.68%, for primary malignant tumors 89.09% and was 100% for metastatic bone tumors.

Conclusion: FNAC of bone tumors was proved to be safe, rapid, useful, inexpensive pre-operative procedure and a good experience of team work with Orthopaedic surgeons and Radiologists.

Keywords: Fine Needle Aspiration Cytology (FNAC), Bone Tumors, Benign, Malignant

INTRODUCTION

Fine Needle Aspiration Cytology of skeletal system has relatively lagged behind in contrast to aspiration of most other organs of the body. Though introduced in 1930, further information is restricted to only few articles in subsequent decades. Relative rarity of bone tumors, hesitancy of clinicians and reluctance by pathologists all contributed to it. Many initial skeptic pathologists have later become enthusiastic about FNAC of bone. In contrast to huge amount of time, money and

other resources involved in histopathology, FNAC of bone tumors is emerging fast as rapid, cheap, safe and useful tool for diagnosis of bone tumors. In the present study 74 patients clinically diagnosed to have bone tumors were examined by FNAC. The objectives were to study diagnostic accuracy, to evaluate and establish the FNAC as a routine procedure for bone tumors and to study various smear patterns.^{1,2,3}

MATERIALS & METHODS

In this prospective study of 74 indoor patients of various age groups and both genders clinically suspected to have bone tumors were evaluated by FNAC. Clinical and radiological details were obtained. The study was approved and permitted by ethical committee of the institution.

After written consent and with due precautions FNAC was performed with long length and 21-23 gauge needles and 10 and 20 ml syringes. No premedication or local anaesthesia was used. All cases were studied under radiological guidance as described by various authors. Sites chosen for FNAC were in following order (a) soft tissue extension of tumour, (b) breached or thinned out cortex, (c) lytic component, (d) least dense area of tumour and no rule of thumb was applied for cystic lesions. Needles entering into thinned out cortex gave a peculiar sensation. Even osseous blood was used for studying cell morphology.

Sites of aspiration were Femur (21), Tibia (09), Humerus (07), Ilium (07), Radius (04), Calcaneum (03), Skull (03), Pubic ramus (03), Spine (02), Metacarpal (02), Ulna (02), Rib (02), Scapula (02), Maxilla (01), Sternum (01), Metatarsal (01), Sacrum (01), Fibula (01), Mandible (01) and Phalanx (01).

Whenever tissue fragments were aspirated, smears were prepared with second slide kept over first and were pulled apart with gentle pressure. Some smears were immediately fixed in 95% ethanol and stained by PAP and few air dried smears were stained by H & E and Leishman stain. At times smears were kept for special stain like PAS and for other study as and when required. Clinical and radiological data were taken

into consideration before giving diagnosis. Histopathological correlation was done later.

RESULTS

On FNAC, out of 74 cases, 49 (66%) were malignant, 14 (18.9%) benign and 7 (3.4%) were non-neoplastic bone lesions with four cases had unsatisfactory material. Of the 49 malignant lesions, 42 were primary and 7 were metastatic bone malignancies. Amongst 14 benign bone tumors, 12 were giant cell tumors of bone and one each of enchondroma and melanotic progonoma. Primary malignant bone tumors were classified as osteogenic sarcoma, Ewing's sarcoma, chondrosarcoma, plasma cell myeloma, admantinoma and other sarcomas (Table. 1). Osteogenic sarcoma were diagnosed in 16 out of 19 cases. The smears were highly cellular, showed pleomorphic spindle to round cells resembling osteoblasts. Osteoid like material was seen in 13 cases. Numerous mitotic figures, tumour giant cells and osteoclastic giant cells were seen (Fig. 1).

In 5 cases out of 7 reported as chondrosarcoma, FNAC yielded bluish translucent slimy material. Cytologically they revealed predominantly single cells with abundant eosinophilic vacuolated cytoplasm. Chondroid matrix was seen as a blue green background with scattered clear bubbles around cells. Pleomorphic cells with multiple nuclei were seen (Fig. 2). Ewing's sarcoma showed monomorphous, dissociated single cells round to oval with rounded small nuclei and finely granular chromatin (Fig. 3). Intra-cytoplasmic glycogen was demonstrated by PAS stain. Out of 5 plasma cell myeloma, four were labeled as multiple myeloma and other was a solitary plasmacytoma. The smears were hypercellular with abundant plasma cells and at many places dividing plasma cells were seen (Fig. 4).

Aspirate from admantinoma was cellular with large polygonal small epithelioid cells and fusiform cells. Four sarcomas were cytologically unclassified. Metastatic bone tumours showed deposits from squamous cell carcinoma (Fig.5), papillary carcinoma thyroid and invasive duct carcinoma of breast. Smears from giant cell tumours of bone showed abundant osteoclastic giant cells with more than 50 nuclei. Stromal cells were spindle shaped without nuclear atypia (Fig.6). No diagnostic material could be aspirated from osteochondroma. FNAC from enchondroma had scanty cellularity on a large mass of metachromatic stroma, uniform cells round to elliptical with clear cytoplasm. Melanotic progonoma showed large round to oval cuboidal cells with melanin deposits in cytoplasm.

CYTOHISTOPATHOLOGIC CORRELATION

Out of 19 clinically and histologically diagnosed cases of osteogenic sarcoma, 16 were correctly diagnosed on FNAC

(Table 2). Out of 12 FNAC diagnosed Ewing's sarcoma 11 were confirmed by histopathology. 5 cases of chondrosarcoma reported on FNAC out of 7, were confirmed on histopathology. 5 out of 5 plasma cell myeloma and 4 other sarcomas were confirmed on histopathology. Admantinoma was also confirmed. Metastatic deposits were correctly diagnosed in all cases. Unsatisfactory smears were seen in 4 cases, one each of osteogenic sarcoma, Ewing's sarcoma, chondrosarcoma and osteochondroma.

There were no false positive reports but 7 cases with false negative reports were noted. The false negative diagnosis included 2 cases of osteogenic sarcoma, 1 chondrosarcoma, 1 giant cell tumour and 3 cases of osteochondroma (Table 3). This could have been because of selection of improper site, blind procedure, irradiation, inflammation or sclerotic lesion and inexperience. A case of chondrosarcoma reported benign was due to a soft tissue mass being hit with underlying fracture missed and showed only chondrocytes and chondroid matrix with inflammatory cells. A case of giant cell tumour had cystic change and yielded haemorrhagic tap with scanty cellularity. Three cases of osteogenic sarcoma were labeled malignant on FNAC but were typed as pleomorphic metastatic carcinoma, malignant fibrous histiocytoma and a giant cell tumour, as osteoid was not seen. A case of Ewing's sarcoma was missed due to atypical presentation and morphology.

Table. No. 1 Showing cytological diagnosis

CYTOLOGIC DIAGNOSIS	NO. OF CASES
1) BENIGN BONE TUMORS	14
Giant cell Tumors	12
Chondroma	01
Melanotic Progonoma	01
2) PRIMARY MALIGNANT BONE TUMORS	49
(A) <u>PLEOMORPHIC TUMORS</u>	
Osteogenic sarcoma	16
Chondrosarcoma	05
Other sarcomas	04
(B) <u>ROUND CELL TUMORS</u>	
Ewing's sarcoma	11
Plasma cell Myeloma	05
(C) Admantinoma	01
3) METASTATIC BONE TUMOURS	07
4) INCONCLUSIVE	04
TOTAL	74

Table. No. 2 showing CYTOHISTOPATHOLOGIC CORRELATION

CYTOLOGIC DIAGNOSIS	No. Of cases	Cyto	HP	Consistent
BENIGN BONE TUMORS				
Giant cell tumors	13	12	13	12
Osteochondroma	04	00	04	00
Enchondroma	01	01	01	01
Melanotic Progonoma	01	01	01	01
PRIMARY MALIGNANT BONE TUMORS				
Osteogenic sarcoma	19	16	19	16
Ewing's sarcoma	12	11	12	11
Chondrosarcoma	07	05	07	05
Plasma cell Myeloma	05	05	05	05
Other sarcomas	04	04	04	04
Admantinoma	01	01	01	01
METASTATIC BONE TUMORS				
	07	07	07	07
UNSATISFACTORY				
	04	04	00	00
TOTAL	74	74	74	63.(85.13%)

Table no.3 showing FALSE POSITIVE AND FALSE NEGATIVE RESULTS

AUTHORS	Unsatisfactory smears (%)		False Positive (%)
Coley et al (1931)	2.9	3.1	5.7
Thommensen & Freidriksen (1976)	8.3	3.52	4.7
Agrawal & Wahal (1983)	--	17.39	--
Frale (1983)	3.4	5.1	--
Ashokraj & Bhatia (1983)	7.9	--	--
Fanning et al (1985)	--	8.8	--
White et al (1985)	15.7	19.6	--
Present study	5.4	9.45	--

Table no. 4 showing DIAGNOSTIC ACCURACY IN PRESENT STUDY

ACCURACY	PERCENTAGE
Overall	85.13

Benign tumors	73.68
Total Malignant tumors	89
Primary Malignant	85.7
Metastatic	100

Table no. 5 showing DIAGNOSTIC ACCURACY BY OTHER AUTHORS

AUTHORS	DIAGNOSTIC ACCURACY
Valls et al (1948)	79.1 %
Ottolenghi (1955)	84.4 %
Schajowicz & Derqui (1968)	77.1 %
Ayala & Zornova (1983)	78.6 %
Agrawal & Wahal (1983)	82.7 %
Frale (1983)	92.0 %
Ashokraj & Bhatia (1989)	89.0 %
Present study	85.13 %

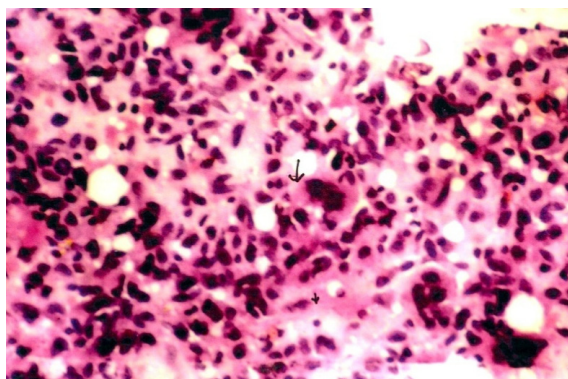


Fig.1 FNAC from Osteogenic sarcoma shows pleomorphic spindle cells with hyperchromatic nuclei and tumour giant cells (Pap 10x X 10x)

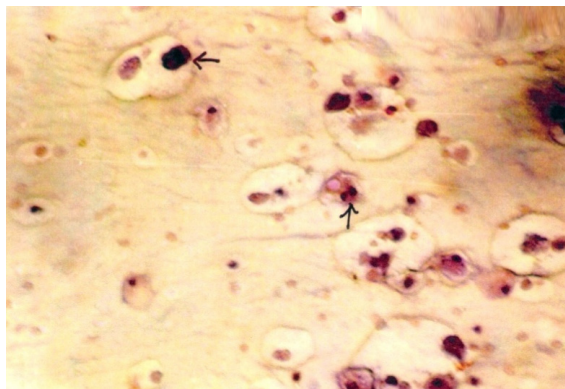


Fig. 2 FNAC from Chondrosarcoma showing chondrocytes in lacunae containing hyperchromatic nuclei (Pap 40x X 10x)

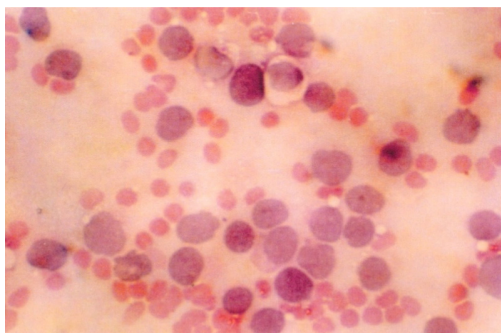


Fig. 3 FNAC from Ewing's sarcoma showing rounded cells with hyperchromatic nuclei (H & E 40x X 10x)

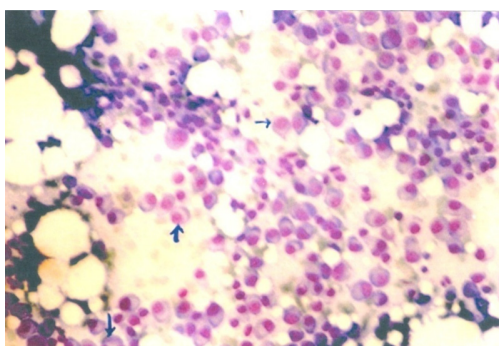


Fig. 4 FNAC from Multiple Myeloma showing mono and binucleate plasma cells with other marrow cells and fat (Leishman 100x X 10x)

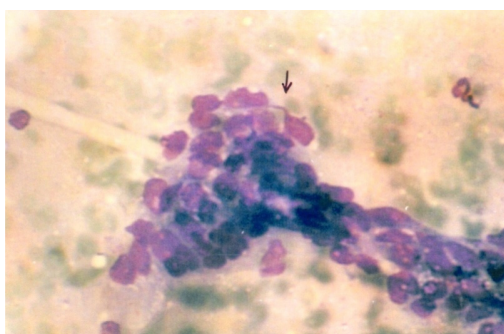


Fig. 5 FNAC from metastatic deposits in bone showing clumps of round to polygonal cells containing hyperchromatic nuclei (Leishman 40x X 10x)

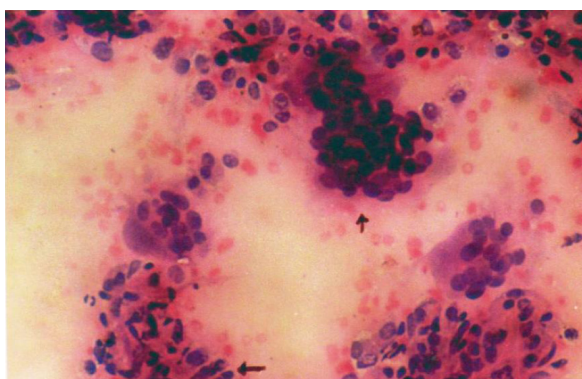


Fig. 6 FNAC from Osteoclastoma showing multinucleate osteoclastic giant cells and spindle cell stroma (Pap 10x X 10x)

DISCUSSION

Proper diagnosis and management of bone tumours requires multidisciplinary involvement by pathologists, radiologists, oncologists and orthopaedic surgeons. Rarity of tumours, various treatment modalities and many groups of cases still requiring histopathological evidence prompted us to seek FNAC of bone tumours for evaluating and establishing the procedure. Biochemical and haematological findings were also considered in myeloma and metastatic carcinomas. Age and gender of patients were vital data.^{4,5,6,7}

FNAC is nowadays widely accepted and applied diagnostic tool. In spite of attempts at bone aspiration from early 1930's, this was not widely used because of unfamiliar cytopathologists. FNAC of bone is mainly successful in diagnosis of malignant tumours. Cytologic features have been previously reported. 3-4 drops of material are adequate to make smears. The combination of Pap, H and E and Leishman stain increased the accuracy^{8,9,10}. Osteoid was better judged with H and E. In our study the diagnostic accuracy for primary bone malignancies was 89.09%, for benign was 73.68%. The results were comparable with other studies. No complications or trauma was noted. No premedication or anaesthesia was used. False negativity was 9.4%. There were no false positive reports.⁶

CONCLUSION

FNAC of bone is a very useful tool when employed with good clinical and radiological input. The procedure was successfully evaluated and established in our institute. It was found to be safe, rapid, inexpensive and very good example of team approach in medicine.

REFERENCES

1. Agrawal P K, Wahal K M . Cytopathological study of primary tumors of bone and joints. *Acta Cytol* 1983; 27(1) : 23-27.
2. Akashraj GA, Bhatia A. Fine needle aspiration cytology in diagnosis of bone tumors. *Ind J Cancer* 1989; 26(4) : 260-64.
3. Ackerman M et al. Fine needle aspiration biopsy in the evaluation of tumorlike lesions of bone. *Acta Orthop Scand* 1976; 47 : 159.
4. Coley BL et al . Diagnosis of bone tumors by aspiration *Am J Surg* 1931 :13(2); 215-24
5. Ayala A G, Zornoza A . Primary bone tumors- Percutaneous needle biopsy. Radiologic-pathologic study of 222 biopsies. *Radiology* 1983; 149 : 675-79.
6. Frable W J. Thin needle aspiration biopsy – A personal experience with 469 cases. *Am J Clin Path* 1976 ; 65 : 168-82.

7. Fanning TV et al . Fine needle aspiration biopsy of Ewing's sarcoma of bone – An analysis of 57 specimen .Acta Cytol 1985 ; 29 : 932.
8. Ottoleghi C E . Diagnosis of orthopaedic lesions by aspiration biopsy – results of 1061 punctures. J Bone Joint Surg1955 ; 37(A) : 449.
9. Schajowicz F, DerquiJ . Puncture biopsy in lesions of the locomotor system. Review results in 5050 cases including 941 vertebral punctures. Cancer 1968 : 21 ; 531-48.
10. Thommerson P, Friedrikson P . Fine needle aspiration biopsy of bone tumors – clinical value . Acta Orth Scand 1976 ; 47 : 137-43.

How to cite this article : Kasture Santosh P, Kulkarni Dinesh R, Kokandakar Hemant R, Bhatambrekar Shrikant V . Fine needle aspiration cytology of Bone tumours in correlation with Histopathology. Perspectives in Medical Research 2018;6(1):56-60.

Sources of Support: Nil, Conflict of interest: None declared