

## Long standing migrated foreign body in neck- A surgeon's nightmare

Savita Larsado<sup>1</sup>, Kuldeep Moras<sup>2</sup>, Preeti Shetti<sup>3</sup>

<sup>1</sup>Assistant Professor, <sup>2</sup>Professor, <sup>3</sup>Postgraduate Student, Department of Otorhinlaryngology, Father Muller Medical College, Kankanady, Managalore.

Address for correspondence: Dr Preeti Shetti, Postgraduate Student, Department of Otorhinlaryngology, Father Muller Medical College, Kankanady, Managalore.

Email – drpreetishetti@gmail.com

### ABSTRACT

Foreign body ingestion is a most frequent clinical emergency requiring quick action to ensure speedy recovery and minimize the complications. At times, if foreign bodies are sharp, they can pierce the wall of pharynx, oesophagus and may appear extraluminally either in the wall or in the soft tissues of neck. Migrated foreign bodies are very rare but may result in life threatening suppurative or vascular complications. Hence removal at the earliest is essential. We present a rare case of one month old neglected migrated foreign body in the left side of the anterior neck which was removed successfully by neck exploration.

**Keywords:** Foreign body, Extraluminal migration, Anterior neck, Metallic wire, CT scan

### INTRODUCTION

Most ingested foreign bodies pass naturally through gastrointestinal tract, but 10-20% require non operative intervention and less than 1% requires surgical intervention.<sup>1</sup> Ingested foreign bodies most commonly get lodged in the upper aero digestive tract, but only a few of these neglected foreign bodies may perforate the oesophagus and migrate extraluminally. Migrated foreign bodies even though rare, are potentially life threatening and challenging to the otolaryngologist. Many neglected foreign bodies migrate extraluminally and appear in anterior part of soft tissue of neck. Even though the incidences are rare, they need appropriate treatment to avoid life threatening complications.

### CASE REPORT

41year old female presented with history of difficulty in swallowing and swelling in the neck since 1 month which was associated with pain and fever. There was no obvious history of foreign body ingestion.

Routine Ear, Nose and Throat Examination were normal. Indirect laryngoscopy did not reveal any foreign body, growth, edema, congestion or pooling of saliva. On neck examination a diffuse fullness was seen in the left side of the neck which was non tender. There was no local rise of temperature, no crepitus and no restricted neck mobility.

Blood investigations were within normal limits. USG of neck revealed an Hypoechoic lesion between cricothyroid membrane and carotid vessels. To rule out foreign body, X-Ray Neck AP View and lateral view was taken and it showed linear metallic wire in the cervical esophagus on the left side measuring approximately around 4cm.

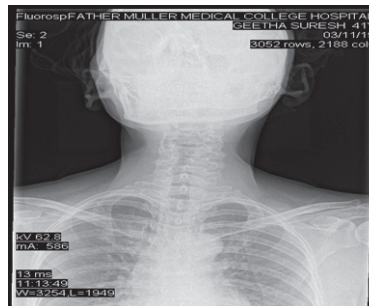


Fig 1: Arrow mark showing foreign body on AP view of X ray neck

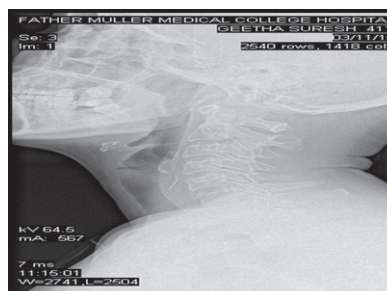


Fig 2 :Arrow mark showing foreign body on lateral view of X ray neck

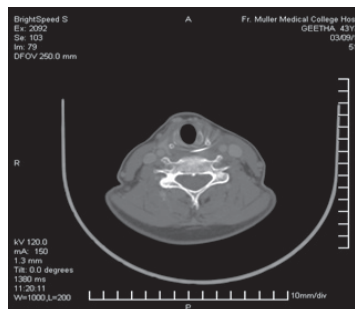
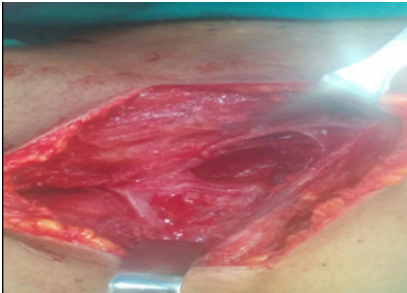


Fig 3: Arrow mark showing foreign body on CECT Neck

Patient was hospitalized and underwent pharyngoesophagoscopy under general anesthesia and no obvious foreign body was seen intraluminally. In view of extraluminal position of foreign body and close relation to jugular and carotid vessels, an open neck exploration was done under GA.



**Fig 4: Arrow mark showing foreign body intraoperative**



**Fig 5: The metallic wire foreign body found**

A 3cm metallic wire was retrieved from just below the level of cricoid cartilage, which had pierced the esophageal wall and was lying across the carotid sheath.

#### DISCUSSION

Ingested foreign bodies most of the time get lodged in the base of the tongue, vallecula, pyriform fossa, cricopharynx and upper oesophagus and need removal under general anesthesia.<sup>2</sup> Rarely neglected foreign bodies can lead to life threatening complications by penetrating gastrointestinal tract and can become lodged in the soft tissues of the neck.<sup>3,4</sup> Remson et al in 1983 reported that out of 321 cases of penetrating esophageal foreign bodies, 43 of them migrated extraluminal.<sup>5</sup>

Extraluminal foreign bodies are most commonly sharper, slender and lie more horizontally so can easily penetrate the wall of the aero digestive tract.<sup>5</sup> Once after perforation, migration may be due to movement of neck muscles and viscera during voluntary or involuntary movements of head and neck structures. Higher rates of penetration are seen in hypopharynx and cervical esophagus due to strong contraction of hypopharyngeal and cricoesophageal muscles as they help propel of food bolus into the esophagus.<sup>6</sup>

Perforated and migrated foreign bodies can introduce microorganisms both aerobic and anaerobic into the soft tissue of the neck which lead to suppurative complications. Infection can spread to mediastinum, leading to life threatening complications like mediastinitis. They might also penetrate major neck blood vessels leading to vascular complications like carotid or Internal jugular vein rupture.<sup>7</sup>

Migrated foreign body need prompt radiological evaluation and removal at the earliest. X ray of soft tissues of the neck is helpful.<sup>8</sup> A CT scan is ideal to localize the foreign body and to determine the extent of damage already occurred and to plan for surgery. It's also guide the surgeon to know the exact size, shape, type, orientation and relationship with surrounding structures like carotid artery, internal jugular vein, thyroid cartilage.<sup>9</sup>

Having radiographic evidence of extraluminal foreign body, is essential for exploration and removal of foreign body via external approach, to prevent further complications.<sup>10</sup>

In our case, history wise there was no of ingestion of foreign body, but on evaluation and neck exploration it was found to be a 3 cm long metallic wire lying below the level of cricoid cartilage, which had pierced the esophageal wall.

#### CONCLUSION

Extraluminal migrated foreign bodies are rare, but potentially life threatening. A careful radiological evaluation detects extraluminal migration. Prompt surgical removal by neck exploration is warranted to avoid further life threatening vascular and airway complications.

#### REFERENCES

1. W.A.Webb. "Management of foreign bodies of the upper gastrointestinal tract:update" *Gastrointestinal Endoscopy* 1995; 41(1):39-51.
2. Arora S, Sharma JK, PippalSK . An unusual foreign body (sewing needle tip) in the tonsils. *Braz J otorhinology (Impr)*, 2007;75(6): 33-35.
3. RutaShanmugum, VellaveduShanmugum et al. Migrating Foreign body in the neck Penetrating the neck muscle. *Sch J Med Case REP* 2015; 3(5): 393-395.
4. Al-Sebeih K, Volvoda M, Sobeih A, Al-Sihan M. Perforating and migrating pharyngo-esophageal foreign bodies: A series of 5 patients. *Ear Nose Throat J* 2006 Sep; 85(9): 600-03.
5. Remsen K, Lawson W, Biller HF, Som ML. Unusual presentation of penetrating foreign bodies of upper aerodigestive tract. *Ann otol Rhino LaryngolSuppl* 1983;105:32-44.

6. Divya GM, Hameed AS, Ramachandran K, Vinayak KV. Extraluminal migration of foreign body: A report of two cases. *Int J Head Neck Surg.*, 2013; 4(2): 98-101.
7. Zohra T, Ikram M, Iqbal M et al. Migrating foreign body in the thyroid gland, an unusual case. *J Ayub Med Coll Abbottabad* 2006; 18(3): 65-66.
8. Lue AJ, Fang WD, Manolidis S. Use of plain radiography and computed tomography to identify fish bone foreign bodies. *Otolaryngol Head Neck Surg* 2000; 123(4):435-38.
9. Vamashankar H, Nair AB, Rajan N. Metallic foreign body penetrating the carotid sheath. *Malaysian J Med Sci.*, 2011;18(1):72-75.
10. Vadhera R, Gulati SP, Garg A, Goyal R, Ghai A. Extraluminal hypopharyngeal foreign body. *Indian Journal of Otolaryngology and Head and Neck surgery* 2009;61: 76-8.

**How to cite this article :** Savita L, Kuldeep M, Preeti S. Long standing migrated foreign body in neck- A surgeon's nightmare. *Perspectives in Medical Research* 2017;5(3):77-79.

**Sources of Support:** Nil, Conflict of interest: None declared