

## Virchow's node : A mystery in young adults

Ritesh Sulegaon<sup>1</sup>, Dinesh Kulkarni<sup>2</sup>

<sup>1</sup>Assistant Professor, <sup>2</sup>Associate Professor, Department of Pathology, Bidar Institute of Medical Sciences, Bidar, Karnataka, India

Address for correspondence: Dr. Dinesh Kulkarni, Associate Professor, Department of Pathology, Bidar Institute of Medical Sciences, Bidar, Karnataka, India. cell : 09850018299

e-mail : drdineshkulkarni@gmail.com

### ABSTRACT

Virchow's node is a lymphnode in (Lt) supraclavicular fossa. It receives lymphatic supply from abdominopelvic region and hence it's abnormal enlargement signifies metastasis from primary malignancy either in gastrointestinal tract or genitourinary tract. Apart from the commonly recognized primary sites, 4.5-5% of primary testicular cancers are also known to metastasize to the left supraclavicular lymph node. This case report throws light on the importance of considering primary germ cell tumor of the testis as one of the differential diagnoses, while aspirating a Virchow's lymph node, especially in young male patients besides emphasizing the need for a thorough clinical examination.

**Keywords:** Virchow's node, metastasis, germ cell tumour, testis

### INTRODUCTION

Testicular germ cell tumors are most common malignant tumors of young men. Most of these tumors present with progressive painless enlargement of testis. These tumors locally spread to tunica albugenia, invade hilum and spermatic cord. They also spread through lymphatics to periaortic and iliac lymph nodes and later to mediastinal and left supraclavicular (Virchow's) nodes. They grow slowly or very rapidly with metastasis to retroperitoneum, mediastinum or lungs, as the tumor size does not correlate with rate of metastasis.<sup>1-4</sup>

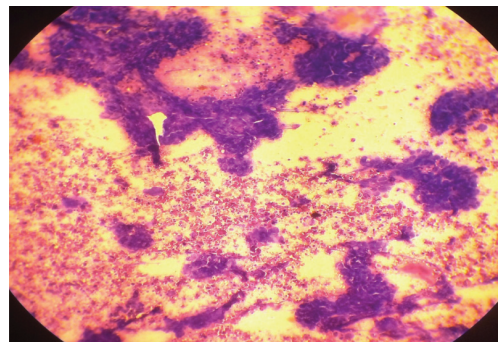
All germ cell tumors arise from seminiferous tubular (germinal) epithelium of mature or maturing testis. Non seminomatous germ cell tumors (NSGCT) are thought to arise from embryonal cells as their pattern of differentiation is directed towards components of embryo or related structures. The basic patterns of NSGCT are embryonal carcinoma, mature and immature teratoma, choriocarcinoma and yolk sac tumor. Mixed NSGCT term is used for tumors exhibiting two or more patterns.<sup>3</sup> Our case highlights importance of thorough history taking and clinical examination while interpreting smears from left supraclavicular lymphadenopathy.

### CASE REPORT

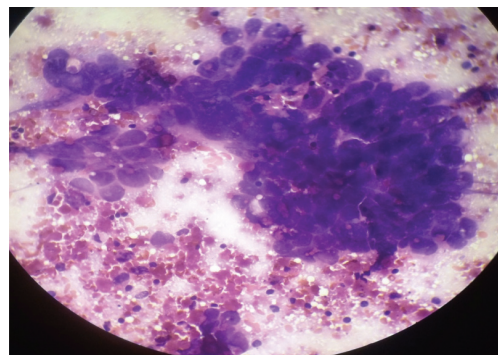
A 24 year male was referred for Fine Needle Aspiration Cytology (FNAC) of (Lt) cervical lymphadenopathy. The swelling was 2x2 cm firm and mobile. He was well built and appeared

physically fit for the procedure. Informed consent was taken and under all aseptic precautions FNAC of (Lt) supraclavicular node was performed with 10 ml syringe and 22 gauge needle. The material obtained was haemorrhagic which was spread on glass slides, were immediately fixed and stained with H & E stain. The smears were examined under the microscope.

Multiple smears were prepared and studied with H & E stain were highly cellular consisting of groups and sheets of large round to oval cells with large hyperchromatic nuclei and at places abundant vacuolated cytoplasm with scattered lymphocytes and RBCs in background (Fig.1&2). The diagnosis of positive for malignant cells likely to be metastatic deposits, advised to search for primary was made.



**Fig. 1:** Shows sheets and groups of large cells with hyperchromatic nuclei and scattered lymphocytes and RBCs in the background. (H & E, 10x)



**Fig. 2:** Higher magnification from same field reveals very large cells with bizarre nuclei with RBCs and lymphocytes in the background (H & E, 40x)

Before dispatching the report, we asked the patient regarding swelling anywhere else in the body, any investigation like USG, CT scan done. To our surprise he produced a histopathology report stating left orchidectomy for epididymo-orchitis – revealing malignant germ cell tumor with yolk sac and embryonal carcinoma components with ITGCN, limited to testis, no lymphovascular invasion, spermatic cord not involved and TNM pT1NxMx.

When asked in detail, he narrated to having (Lt) testicular swelling for one and a half year which went on increasing to attain a large size. The ultrasonography (USG) of (Lt) testis suggested it to be granulomatous orchitis. He also noticed swelling in the left side of neck since 15 days. The ENT surgeon examined him and thought it to be of infective origin and prescribed him antibiotics and called him for a follow up. But in the mean time patient approached the surgeon who performed high (Lt) Orchidectomy. As the neck swelling was still persistent postoperatively, the patient was referred to us for FNAC.

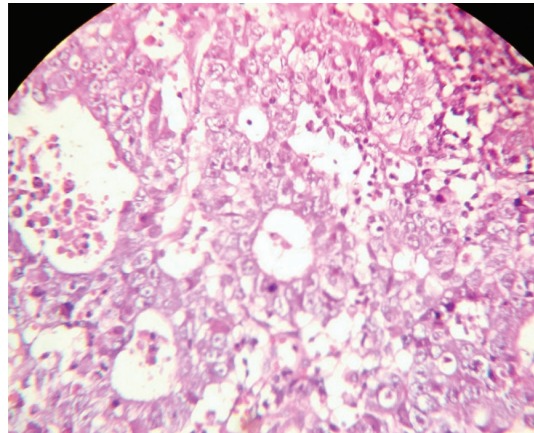
#### DISCUSSION

Virchow's node receives lymphatic supply from abdominopelvic region. The finding of enlarged hard node, also referred to as Troisier's sign has long been regarded as strongly indicative of presence of malignant neoplasm in abdominopelvic region. The germ cell tumors of testis are known to spread through lymphatics and show metastatic deposits in left supraclavicular i.e. Virchow's nodes. Young patients with painless testicular swelling and (Lt) supraclavicular lymphadenopathy, must be evaluated to rule out metastasis.<sup>2</sup>

Approximately 95% of all testicular neoplasms are of germ cell origin. For unclear reasons, there has been a worldwide increase in the incidence of these tumours. More importantly, Testicular tumours are the most common malignant diseases, developing in men between 20 and 40 years of age and are the third leading cause of death among men of this age group.<sup>4</sup>

Neck metastasis are rare from testicular tumour, hence clinicians and pathologists may overlook metastatic deposits from germ cell tumors of testes in left supraclavicular lymphadenopathy. But a possibility of metastatic germ cell tumour must be kept in mind especially in young males.<sup>2</sup>

We reviewed the histopathology slides and also took deeper sections, and we too diagnosed it to be malignant germ cell tumour of testis with predominant embryonal carcinoma component without lymphovascular invasion (Fig. 3). Even though thorough sectioning from tumor mass did not reveal vascular or lymphatic invasion, distant metastasis clearly explains microinvasion, which could be missed even after multiple sections and extensive search for tumor emboli.



**Fig.3** Section reveals tumor tissue arranged in glandular pattern lined by large round to oval cells with hyperchromatic nuclei and vacuolated cytoplasm (H & E 40x ), revealing cells in Virchow's node FNAC.

#### CONCLUSION

Irrespective of age, (Lt) Supraclavicular lymphadenopathy must be evaluated thoroughly with clinical examination and supportive investigations like USG, CT scan, etc. along with at least FNAC of node and then only the patients be subjected for further treatment. We stress on clinicopathological correlation for evaluation of Virchow's nodes in determining abdomino-pelvic and testicular malignancies, especially in young adults.

#### REFERENCES

1. Kumar, Abbas, Fausto, Mitchell. The Male Genital System. In :Robbins Basic Pathology, 8th edition. Pennsylvania: Saunders , 2007 : 690.
2. A. L. Hemalatha, Nishtha Batra, Deepthi. B. Ramesh and S. D. Shashikumar. "Virchow's Node Not Always Signifies a Primary Gut or Lung Malignancy. Look Further and Farther," International Journal of Case Reports in Medicine (2013) Article ID 616832.
3. Rosai J. Male reproductive system. In: Rosai J, eds. Rosai and Ackerman's Surgical Pathology. 9 th ed. St. Louis, Missouri: Mosby Co.; 2005: 1417-1444.
4. Kumar SV et al. Int J Res Med Sci. 2015 Jan;3(1):327-330.

**How to cite this article :** Sulegaon R, Kulkarni D. Virchow's node : A mystery in young adults. Perspectives in Medical Research 2018; 6(3):78-79.

**Sources of Support:** Nil, Conflict of interest: None declared