

Conservative management of urethral prolapse in a five year old girl: A case report

A Sarojini¹, Subha Ranjan Samantaray², Ipsita Mohapatra², Achanta Vivekanand³

¹Associate Professor, Department of Obstetrics and Gynaecology, ²Assistant Professor, Department of Obstetrics and Gynaecology, ³Professor, Department of Obstetrics and Gynaecology, Prathima Institute of Medical Sciences, Karimnagar, Telangana, India. Corresponding Author: Dr. Subha Ranjan Samantaray, Assistant Professor, Department of Obstetrics and Gynaecology, Prathima Institute of Medical Sciences, Telangana, India.

Email: dsubha2009@gmail.com

ABSTRACT

Urethral prolapse is a rare presentation. Among all the age groups it is commonly seen in prepubertal age. Most cases are asymptomatic, but if they present, the most common presentation is vaginal bleeding. We present a case of a 5 year old girl who presented with vaginal bleeding and a mass in the vulva. Examination under anaesthesia was done and final diagnosis was made as urethral prolapse.

Conservative medical management was planned, with daily sitz bath along with local application of topical antibiotic and estrogen cream. The mass decreased in size within 3 weeks and the bleeding was completely subsided. Urethral prolapse can be managed conservatively in young and uncomplicated cases. Though surgery is the treatment of choice with minimal chance of recurrence, each case should be individualized and treated.

Please cite this article as: Sarojini A, Samantaray SR, Mohapatra I, Vivekanand A. Conservative management of urethral prolapse in a five year old girl: A case report. *Perspectives in medical research* 2014;2: 31-33

Source of Support: Nil, Conflict of interest: None Declared

INTRODUCTION

Urethral prolapse is a complete circular eversion of the urethral mucosa through the external urethral meatus resulting in congestion and edema of prolapsed part and usually presents as a reddish purple mass through vulva which bleeds intermittently. It may be considered as a sliding hernia of urethra upon its supporting structures.¹ Only females are affected. The first case of urethral prolapse was noted by Solingen et al in 1732 and later Zeigerman et al reported 5 cases in 1945.^{2,3} urethral prolapse has an estimated incidence of about 1/3000.⁴ It is seen commonly in prepubertal native African girls and postmenopausal white women.⁵ Around 80% of the cases are seen in pediatric population, among them the common age of presentation is between 6 months to 8 years.⁶ Second highest incidence is seen between 60 and 65 years.⁷ The youngest reported case of urethral prolapse was 5 day old neonate and oldest was seen in a 92 years old lady.

Most of the cases of premenarcheal urethral prolapse are asymptomatic but if they present the

predominant feature is vaginal bleeding. Other symptoms include dysuria, increased frequency and urgency of micturation, difficulty in voiding, nocturia and sometimes tenesmus.¹ Onset may be acute or chronic. Acute presentation is seen in both children and old aged patients. Chronic prolapse is seen commonly in old age.⁸

Urethral prolapse can be diagnosed by its typical clinical appearance. On examination, it appears as a doughnut shaped reddish purple mass protruding through vulva with a central opening of the external urethral meatus.⁶ It can be confirmed by foley's catheterization. We are reporting a case of urethral prolapse in a 5 year old girl.

CASE REPORT

A 5 year old girl presented to the department of obstetrics and gynaecology, Prathima Institute of Medical Sciences, in the month of July 2014 with the complaints of vaginal bleeding and a mass protruding from vulva since 3 days which was noticed by her mother (figure 1). There was no associated complain like pain abdomen, foul

smelling vaginal discharge, cough, fever. She also did not have any complain of frequency, urgency, nocturia or any other lower uterine symptoms. There was no history of sexual abuse or trauma. Her vitals were stable. On physical examination a small reddish, edematous mass protruding from the vestibule was observed (figure 2). Examination under anaesthesia was planned on the next day, which revealed a reddish mass in the region of urethra protruding with a central opening. Foley's catheterization (size 10Fr) was done through the opening and 80 ml of urine was collected. This confirmed that the opening visible through the mass was external urethral meatus (figure 3). Final diagnosis was made as urethral prolapse. All routine investigations were done and found to be normal, urine culture and sensitivity was showing no growth.

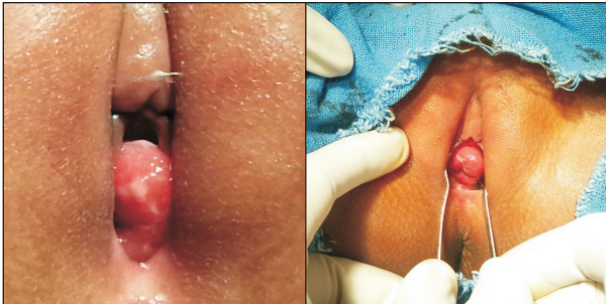


Figure -1

Figure -2

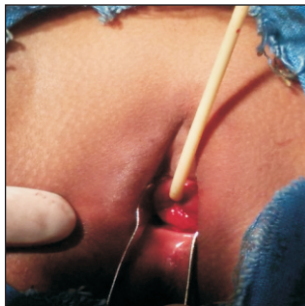

Figure -3

Figure 1: An erythematous mass was noted protruding from the vulva

Figure 2 : Per speculum examination revealed a central opening

Fig 3: Catheterization confirms the mass as urethral prolapse

Rectal examination was done and no abnormalities were detected. The catheter was kept in place for 3 days. Conservative medical management was planned, with daily sitz bath along with local application of topical antibiotic and estrogen cream. The catheter was removed after 3 days and the patient was discharged. She was advised to continue the estrogen cream for 3 weeks. Follow up was done after 3 weeks. The mass decreased in size and the bleeding

completely subsided. We are regularly following the case for any recurrence.

DISCUSSION

Etiology of urethral prolapse is not clear, but the possible causative factors include mucosal redundancy, estrogen deficiency, inadequate perineal muscular attachment and increased intra-abdominal pressure. Other contributing factors are trauma, malnutrition, urinary and vaginal infection, chronic cough and constipation, neuromuscular weakness. Valerie hypothesized that the high resting intra-abdominal pressure in children that are large for their age is one of the causes.⁹ Popularly this condition is thought to be aetiologically analogue of hernia at any other site and it may be caused due to congenital weakness of the supporting tissues.¹⁰

Onset is usually acute and the common presenting symptoms are vulval mass, spotting or bleeding or serosanguinous discharge from the vulva. As the disease progresses the edema and congestion become more severe, finally thrombosis and sloughing may occur. The diagnosis is based on clinical features of circumferential edematous, reddish purple tissue prolapsing through the urethral meatus. Laboratory and radiological evaluation are not necessary in most of the cases.^{9,11}

The condition may mimic like some other pathology like urethral caruncle, rhabdomyosarcoma, ectopic urethrocele, condyloma, sarcoma botryoides, endodermal sinus tumor, urethral malignancy, urethral leiomyoma, malakoplakia and foreign body.¹² The optimal treatment for urethral prolapse is still a controversy; options are medical or surgical methods. Medical methods include sitz bath, local hygiene, topical steroid, topical estrogen, and topical antibiotics. Surgical treatment is required in more severe and complicated cases or after failure of medical therapy. Different surgical methods are ligation of mucosa over a catheter, cauterization of the mucosa and excision of the mucosa with a catheter in situ. Other methods are cryosurgery and reduction of prolapse through a vaginal incision followed by suturing of circular muscle around distal urethra, four quadrant excision technique. Some complications may be seen after surgical treatment like urethral stenosis, urinary incontinence, urinary retention, vaginal bleeding, bleeding from suture line and recurrent prolapsed.⁹ Medical management may not be always be effective and is having a high rate of recurrence. Surgery is the treatment of choice with high cure rate.^{13,14,15}

Our case was a five year child with an acute presentation of vulval mass with vaginal bleeding without any associated complaints. Clinical examination and examination under anesthesia confirmed that it is a case of urethral prolapse. The exact cause could not be identified, however after excluding the common causes we came to a conclusion that, the prolapse may possibly caused by intrinsic weakness of supporting structure. As our case is a young premenarcheal child without any other complication like ulceration, thrombosis or infection, rather than planning for surgery, we had planned to manage the case conservatively with sitz baths, topical antibiotic and estrogen with regular follow up. After 3 weeks the symptoms as well as the mass decreased in size. After 4 months she was completely asymptomatic and the vulval mass significantly decreased in size. We are doing a regular follow up to detect any recurrence.

CONCLUSION

Urethral prolapse is a rare condition which is usually diagnosed by clinical examination. Conservative/medical management may be tried in young and uncomplicated cases. Though surgery is the treatment of choice with minimal chance of recurrence, each case should be individualized and treated.

REFERENCES

1. Burns E. The clinical importance of congenital anomalies of the urinary tract. *Nebr MJ* 1950;35:246.
2. Herbut P A. *Urologic Pathology*, Lea and Febiger, Philadelphia, 1952.
3. Zeigerman JH. Prolapse of the female urethra: Its differential diagnosis with report of 5 cases. *Urol and Cut Rev* 1945; 49:403.
4. Mitre A, Nahas W, Gilbert A, Glina S, Saiovici S, Mazzucchi E et al. Urethral prolapse in girls Familial care. *J Urol*. 1987 Jan;137(1):115.
5. Epstein A, Strauss, B. Prolapse of the female urethra with gangrene. *Am J Surg* 1937; 35: 563 - 565.
6. Arzarian AE, Arzarian AY. Urethral prolapse: report of a case, proceedings of UCLA healthcare 2010; 14:1-2.
7. Dunn WJ, Russel Malinak L. Spontaneous urethral prolapsed. *Calif Med*. Nov 1963; 99(5): 338-340.
8. Cardozo L. Urinary incontinence and other disorders of the lower urinary tract in women. In: Dewhurst's textbook of Obstetrics and Gynaecology for Postgraduates. 5th Ed. Ed. C.R. Whitfield. Blackwell Scientific. Oxford. 1995 Pp 653 -680.
9. Valerie E, Gilchrist BF, Frischer J, Scriven R, Klotz DH, Ramenofsky ML. Diagnosis and treatment of urethral prolapse in children. *Urology* 1999;54(6):1082-4.
10. Peters William A. Prolapse of the urethral mucosa, *Am J Obst and Gynec* 1962;84:862.
11. Shurtleff, BT, Barone JG. Urethral prolapse: Four quadrant excisional technique. *J Paed Adolescent Gynaecology* 2002; 15(4): 207 – 211.
12. Anveden-Hertzberg L, Gauderer MW, Elder JS. Urethral prolapse: an often misdiagnosed cause of urogenital bleeding in girls. *Pediatr Emerg Care* 1995;11:212-4.
13. Park BJ, Kim YW, Kim TE, Lee DH. Urethral prolapse in a premenarchal Asian girl. *Obstet Gynecol* 2009;113:506-7.
14. Shavit I, Solt I. Urethral prolapse misdiagnosed as vaginal bleeding in a premenarchal girl. *Eur J Pediatr* 2008; 167(5):597-8.
15. Hillyer S, Mooppan U, Kim H, Gulmi F. Diagnosis and treatment of urethral prolapse in children: experience with 34 cases. *Urology*. 2009;73(5):1008-11.